

The first case of human otoacariasis in Cyprus



Hasan Safakogullari ¹, Özge Özden ^{2,*}, Wayne J. Fuller ³

¹Department of Otorhinolaryngology, Faculty of Medicine, Near East University, Nicosia, Cyprus

²Cyprus Herbarium and Natural History Museum, Near East University, Nicosia, Cyprus

³Faculty of Veterinary Medicine, Near East University, Nicosia, Cyprus

ARTICLE INFO

Article history:

Received 26 June 2020

Received in revised form

4 September 2020

Accepted 6 September 2020

Keywords:

Ear infestation

Acari

Mites

Dermatophagoides

Medical

Cyprus

ABSTRACT

Otoacariasis is the ear canal infestation by the arthropod Subclass: Acari, usually ticks or mites. It is a common complaint seen in animals. However, there are relatively few documented cases of human otoacariasis. In August 2019, a physically healthy 53-year-old Cypriot man visited Near East University hospital complaining of a blockage, partial deafness, and minor pruritis in his left ear. During the examination of the patient, a mite infestation of his left external auditory canal (EAC) was determined. The mites were removed from the EAC and sent to the laboratory for identification. The mite samples were viewed under Olympus-CX31 light microscopy and identified as *Dermatophagoides pteronyssinus*. The patient was treated with Permethrin (cream), Xylocaine spray, dilute acetic acid (vinegar), and three ear canal aspirations. After three days, the patient's ear was re-examined, and the number of mites had greatly decreased within the EAC. Follow up consultations confirmed the eradication of the mite infestation. This is the first case report of human otoacariasis from Cyprus.

© 2020 The Authors. Published by IASE. This is an open access article under the CC BY-NC-ND license (<http://creativecommons.org/licenses/by-nc-nd/4.0/>).

1. Introduction

Otoacariasis is an infestation of the external auditory canal (EAC) by ticks or mites. It is a common complaint among domestic and wild animals (Degiorgis et al., 2001; Yeruham et al., 1985). However, it is less commonly recorded in humans (Al-Arfaj et al., 2007; Dilrukshi et al., 2004). Most previous cases of human otoacariasis are case reports, with the more common infestations being parasitic ticks (Dilrukshi et al., 2004; Cakabay et al., 2016) and only a relatively minor number related to mite infestations (Dilrukshi et al., 2004; Alazzawi et al., 2016; Ueda et al., 2017). Pyroglyphidae is a family of non-parasitic dust mites of which the genus *Dermatophagoides* contains species of house dust mites (HDM). There are two common species from this genus the European dust mite *D. pteronyssinus* and the American dust mite *D. farinae*. House dust mites are distributed ubiquitously across the globe but are rarely found in direct association with the human body, normally living in the vicinity of

humans, feeding on the dead shed skin and organic materials (Arlian and Platts-Mills, 2001). Normally house dust mites do not affect humans. However, they are a significant trigger in cases of rhinitis, asthma, and dermatitis (Arlian and Platts-Mills, 2001; Lau et al., 2000).

As a result of otoacariasis, mites can be present in different life stages such as egg, nymph, and adult (Ueda et al., 2017). The most common symptoms of otoacariasis are usually pruritis, otalgia, blockage of the ear canal. To relieve such symptoms, it may be necessary to provide anti-pruritic, anti-inflammatory, and analgesic medication. In addition to such treatments, the physical removal of the infecting organism is paramount. This can be achieved through flushing the ear canal, ear drops, and the direct removal of the organism and its various life-stages (Ueda et al., 2017; Abi-Aki et al., 2017).

2. Case report

A 53-year-old man from the north-west region of Cyprus, whose occupation was a vehicle recovery business, visited the clinic of Near East University hospital on the 25th August 2019. The patient's symptoms were a blockage in his left ear, resulting in a slight loss of hearing and minor itching. He had no recent history of fever or cough, and his general health was good.

* Corresponding Author.

Email Address: ozge.fuller@neu.edu.tr (Ö. Özden)

<https://doi.org/10.21833/ijaas.2021.01.014>

Corresponding author's ORCID profile:

<https://orcid.org/0000-0001-7938-6927>

2313-626X/© 2020 The Authors. Published by IASE.

This is an open access article under the CC BY-NC-ND license

(<http://creativecommons.org/licenses/by-nc-nd/4.0/>)

During the examination and using a Xion-endovision MD 2111, a video recording revealed hundreds of active mites of varying life stages (adults, nymphs, etc.) and their eggs within the moist inner surface of the External Auditory Canal. Following their removal from the ear canal using a Q-tip, the samples of mites were slide-mounted for microscopic examination. Digital images were taken using light microscopy (Olympus-Cx31, Japan) of the slide-mounted (Figs. 1, 2, and 3). Additionally, during the pre-treatment period, a one-minute video recording was made during otoscopic examinations of the patient. There were no limitations in order to carry out this research.

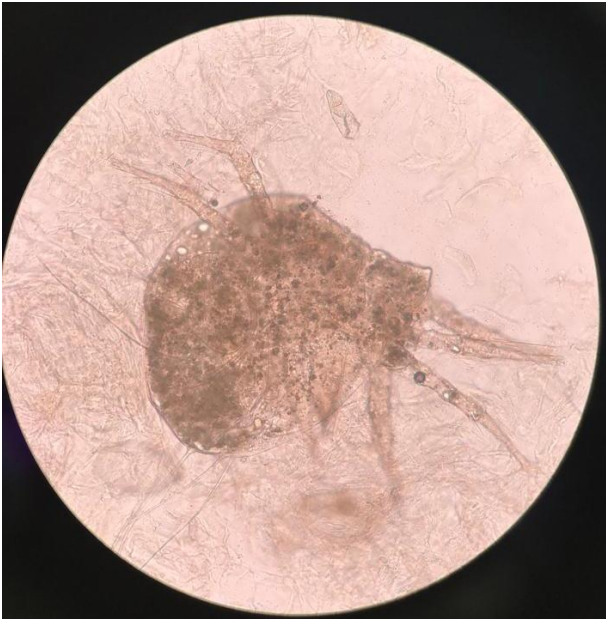

Fig. 1: Adult specimen of *Dermatophagoides pteronyssinus* (European house dust mite)

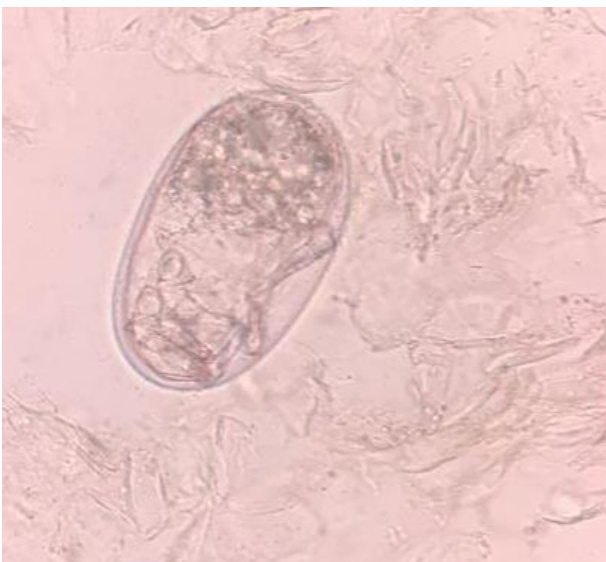


Fig. 2: Egg of *Dermatophagoides pteronyssinus* (European house dust mite)

Examination of the light microscope images and slide-mounted specimens revealed the presence of dust mites, which were identified as *Dermatophagoides pteronyssinus* (European house

dust mite) (Acari: Pyroglyphidae) at NEU Herbarium and Natural History Museum, Dept. of Entomology.

The patient was treated with Permethrin (cream), Xylocaine spray, dilute acetic acid (vinegar), and three ear canal aspirations. After three days, the patient's ear was re-examined, and the number of mites had greatly decreased within the EAC. Follow up consultations confirmed the eradication of the mite infestation.

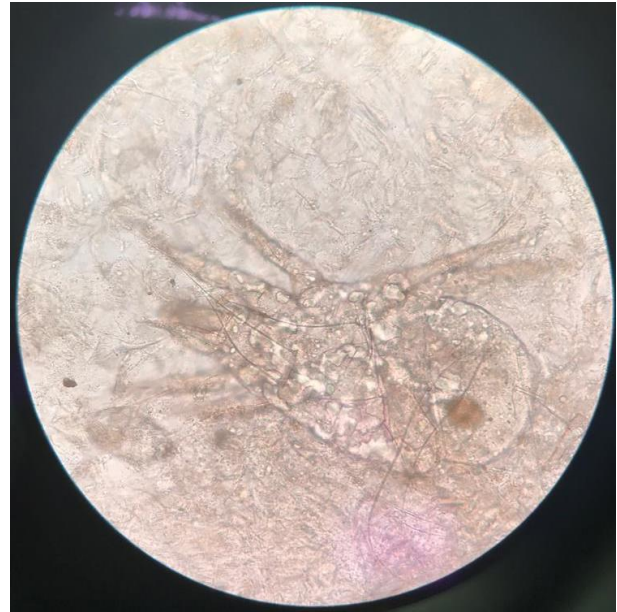

Fig. 3: Adult of *Dermatophagoides pteronyssinus* (European house dust mite)

3. Discussion

Otoacariasis is more commonly associated with domesticated animals (Yeruham et al., 1985). However, on rare occasions, there are reported human cases (Indudharan et al., 1999). Most reported cases, in both humans and animals, are related to ticks (Subclass: Acari; Order: Ixodida) infestations (Dilrukshi et al., 2004; Cakabay et al., 2016), with substantially fewer reports involving mites (Abi-Aki et al., 2017; Sidenius et al., 2002). Many of these interactions have evolved as host/ectoparasite relationships, with many of the parasitic mites or ticks being vectors for a multitude of important infectious diseases in both animals and humans. Although many host/parasite interactions involve the direct feeding of the parasitic organism on the host organism, however, a few parasitic associations with their respective host only involves the parasitic organism residing on the host with no direct invasive feeding from the host. It is arguable as to whether the infestation of dust mites is true parasitism or just a serendipitous event, with the mites' chance utilization of a suitable environment in/on which to complete its lifecycle. House dust mites live in close proximity to humans feeding on flakes of dead skin and other organic detritus (Arlian and Platts-Mills, 2001). The general environment of the ear canal would provide a suitable environment (i.e., warm and humid) in which mite could

successfully inhabit and reproduce (Arlan and Platts-Mills, 2001). Our patient had no specific workplace environment, which would promote such an infestation; we therefore reasonably speculate that the initial contamination came via the patient's domestic residence. The patient was coming from a rural living area in the Guzelyurt region, Cyprus, and surrounded by little farmhouses. House dust mites on known colonizers of soft furnishings, such as pillows, bedding, and cushions, where such contacts are easily made (Nadchatram, 2005).

The initial primary treatment for otoacariasis infestations usually involves the physical removal of the infesting organisms either by direct removal or flushing (Ueda et al., 2017; Cho et al., 1999), followed by some medicated treatments of the resulting symptoms such as inflammation and itching. Often it is not possible to physically remove all individuals and its various life stages (adults, nymphs, and eggs) of the infesting organism during the initial treatment. Therefore, continual daily auricular irrigation or application of pesticide treatments are required over the intervening days/weeks to be sure of the complete eradication of the organisms in question (Ueda et al., 2017). In this case, we used daily applications of a vinegar solution (dilute acetic acid) for auricular irrigation. In some cases, a mild saline solution has been used for the initial flushing of the ear canal, followed by regular application of acetic acid ear drops (Abi-Aki et al., 2017). In conjunction with these daily flushing's, daily topical applications of Permethrin and Xylocaine were administered. Vinegar is not a recommended treatment for such cases. However, dilute acetic acid has been used (Abi-Aki et al., 2017) in this case, and it proved to be highly effective.

Acknowledgment

The authors are grateful to Melis Temizel, who carried out microscope mounting of the specimens.

Compliance with ethical standards

Conflict of interest

The author(s) declared no potential conflicts of interest with respect to the research, authorship, and/or publication of this article.

References

- Abi-Aki P, Haddad G, and Zaytoun G (2017). Otoacariasis: An infestation of mites in the ear. *Annals of Clinical Case Reports*, 2, 1329.
- Al-Arfaj AM, Mullen GR, Rashad R, Abdel-Hameed A, Oconnor BM, Alkhalife IS, and Dute RR (2007). A human case of otoacariasis involving a histiostomatid mite (Acari: Histiostomatidae). *The American Journal of Tropical Medicine and Hygiene*, 76(5): 967-971.
<https://doi.org/10.4269/ajtmh.2007.76.967>
PMid:17488924
- Alazzawi S, Lynn ELY, Ibrahim J, Wee CA, and Raman R (2016). Research note house dust mites in human ear. *Tropical Biomedicine*, 33(2): 393-395.
- Arlan LG and Platts-Mills TA (2001). The biology of dust mites and the remediation of mite allergens in allergic disease. *Journal of Allergy and Clinical Immunology*, 107(3): S406-S413.
<https://doi.org/10.1067/mai.2001.113670> **PMid:11242601**
- Cakabay T, Gokdogan O, and Kocyigit M (2016). Human otoacariasis: Demographic and clinical outcomes in patients with ear-canal ticks and a review of literature. *Journal of Otology*, 11(3): 111-117.
<https://doi.org/10.1016/j.joto.2016.06.003>
PMid:29937819 PMCID:PMC6002594
- Cho JH, Kim JB, Cho CS, Huh S, and Ree HI (1999). An infestation of the mite *Sancassania berlesei* (Acari: Acaridae) in the external auditory canal of a Korean man. *The Journal of Parasitology*, 85(1): 133-134.
<https://doi.org/10.2307/3285717> **PMid:10207379**
- Deigiorgis MP, Hård af Segerstad C, Christensson B, and Mörner T (2001). Otodectic otoacariasis in free-ranging Eurasian lynx in Sweden. *Journal of Wildlife Diseases*, 37(3): 626-629.
<https://doi.org/10.7589/0090-3558-37.3.626>
PMid:11504239
- Dilrukshi PRMP, Yasawardene ADKSN, Amerasinghe PH, and Amerasinghe FP (2004). Human otoacariasis: A retrospective study from an area of Sri Lanka. *Transactions of the Royal Society of Tropical Medicine and Hygiene*, 98(8): 489-495.
<https://doi.org/10.1016/j.trstmh.2003.12.008>
PMid:15186938
- Indudharan R, Ahamad M, Ho TM, Salim R, and Htun YN (1999). Human otoacariasis. *Annals of Tropical Medicine and Parasitology*, 93(2): 163-167.
<https://doi.org/10.1080/00034983.1999.11813406>
PMid:10474641
- Lau S, Illi S, Sommerfeld C, Niggermann B, Bergmann R, von Mutius E, and Wahn U (2000). Early exposure to house-dust mite and cat allergens and development of childhood asthma: A cohort study. *Lancet*, 356(9239): 1392-1397.
[https://doi.org/10.1016/S0140-6736\(00\)02842-7](https://doi.org/10.1016/S0140-6736(00)02842-7)
- Nadchatram M (2005). House dust mites, our intimate associates. *Tropical Biomedicine*, 22(1): 23-37.
- Sidenius KE, Hallas TE, Brygge T, Poulsen LK, and Mosbech H (2002). House dust mites and their allergens at selected locations in the homes of house dust mite-allergic patients. *Clinical and Experimental Allergy*, 32(9): 1299-1304.
<https://doi.org/10.1046/j.1365-2222.2002.01472.x>
PMid:12220467
- Ueda DM, Borges R, and da Silva JEP (2017). Infestation of mites in external auditory canal. *Ear, Nose and Throat Journal*, 96(6): E46-E47.
<https://doi.org/10.1177/014556131709600610>
PMid:28636743
- Yeruham I, Hadani A, and Rosen S (1985). Psoroptic ear mange (*Psoroptes cuniculi*, Delafond, 1859) in domestic and wild ruminants in Israel. *Veterinary Parasitology*, 17(4): 349-353.
[https://doi.org/10.1016/0304-4017\(85\)90026-3](https://doi.org/10.1016/0304-4017(85)90026-3)